

A Peer-Reviewed and Indexed Publication

Compendium

of Continuing Education in Dentistry

SEPTEMBER 2023 | Volume 44, Number 8



Spot-on Diagnosis

Systematically Addressing Joint Pain
While Enhancing Esthetics

KRIS SWANSON, DDS; AND LEON HERMANIDES, CDT

Plus:

**CE: Subcrestal Implantoplasty
for Treating Peri-implantitis**

Paul S. Rosen, DMD, MS; and
Dennis P. Tarnow, DDS

**CE: Evaluating Clinical Trials
to Benefit Patient Care**

Gary Greenstein, DDS, MS; and
John Grbic, DMD, MS, MMSc



What's New in Glue: Utilizing Universal Resin Cement for Non-Ideal Situations in Prosthodontics

Miles R. Cone, DMD, MS, CDT

Abstract: Dentists frequently encounter the need to cement indirect restorations in clinical situations that are less than ideal, and the longevity and predictability of the indirect restorative materials used in such cases is largely predicated on the chemical and/or mechanical bond formed between the natural tooth or abutment and the cement. These non-ideal scenarios have been a significant driver in the continued evolution of self-adhesive resin cements (SARCs) with added functional monomers, such as 10-MDP. This article discusses three real-world case studies in which a newly developed universal SARC was utilized and combined with the use of an optional adhesive-enhancing primer that employs a proprietary “touch-cure” technology, or a light-cured adhesive, to improve the bond strength of the resin cement and enhance patient outcomes.

The increased demand for improved esthetics and better long-term predictability of indirect restorations has led to a greater use of tooth-colored adhesive resin cements among dentists.¹ Resin cements possess a myriad of clinical advantages, including exceptional mechanical properties, high wear resistance, low solubility in the oral cavity, and improved marginal adaptation.²

Advancements in the adhesive chemistry of these luting agents precipitated the subsequent introduction of self-adhesive, dual-polymerizing resin cements. These cements do not require an etchant or adhesive primer and, therefore, offer the additional benefit of reducing the number of clinical steps needed for use; ultimately, they provided a less technique-sensitive and more efficient bonding protocol for the clinician.^{3,4} These cements eliminate the need for an etchant by incorporating special acid-functionalized adhesive monomers into the resin, such as 10-methacryloyloxydecyl dihydrogen phosphate (10-MDP), which allows for the demineralization of the tooth structure and provides a greater chemical affinity to bond to a variety of substrates, including the tooth, base metal alloys, titanium, and zirconia.⁵⁻⁹ This adhesive technology is particularly important in

clinical situations where the natural crown height or available prosthetic structure/support is less than ideal for traditional cementation techniques.

The following three case studies describe common challenges involving indirect restorations and the use of a contemporary universal self-adhesive resin cement (SARC) in combination with a universal light-cured adhesive or adhesive-enhancing primer (AEP) to overcome the challenges.

Case 1: Debonded Full-Coverage Lithium-Disilicate Crown

A 65-year-old female patient presented for diagnostic maxillary and mandibular alginate impressions, which would be used to aid the dental laboratory in the development and fabrication of a wax-up for the replacement of her failing long-span maxillary fixed dental prosthesis (FDP) (teeth Nos. 4 through 13). The patient had a heavily restored dentition on short clinical crowns. She had parafunctional habits (bruxism) but was not currently using a nightguard.

After the mandibular alginate impression was made, it was noted that the full-coverage lithium-disilicate crown on tooth No. 26 had debonded and was embedded in the impression (Figure 1 through Figure 3). The patient

reported no discomfort following the accidental removal of the crown. Debonding of ceramic restorations is not uncommon and has been cited in the literature to be as high as 9%.¹⁰ When ceramic debonds from a tooth, in most cases some of the original resin cement will remain adhered to the intaglio surface of the restoration.¹¹ Prior to re-cementation of the restoration, the existing resin cement must be removed; however, translucent or tooth-shaded resin cements may be difficult to detect. In this case, an ultraviolet light (K-Lite, Smile Line, smilelineusa.com), which exploits the fluorescent properties of the resin, was used to allow the clinician to easily visualize and remove the residual resin cement in preparation for surface treatment (Figure 4).¹²

Once all the existing resin was removed, the following laboratory protocol was used to condition the ceramic restoration: (1) 9.5% hydrofluoric acid-etch of the intaglio surface for 20 seconds,¹³ rinsed and dried; (2) 37% phosphoric acid-etch for 60 seconds, washed and dried; (3) ultrasonic bath in 91% isopropyl alcohol for 5 minutes and dried; (4) silane or

ceramic primer application to intaglio for 1 minute followed by heat evaporation.^{14,15}

Following the proposed instructions for use for the universal SARC (G-CEM ONE™, GC America, gc.dental/america), a single-component light-cured adhesive (G-Premio BOND™, GC America) was applied to a microbrush (Figure 5) and brushed onto the cleaned tooth preparation, coating it, for 10 seconds (Figure 6). Adjacent teeth were isolated with polytetrafluoroethylene (Teflon tape), and the adhesive was air-thinned for 5 seconds and light-cured for 20 seconds. The debonded restoration, with the resin cement inside, was then seated onto the tooth preparation and tack-cured for 1 second (Figure 7). All excess resin cement was carefully removed, yielding an acceptable final result (Figure 8).

Case 2: Cement-Retained Metal-Ceramic Implant Crown

A 55-year-old female patient presented for a professional consultation regarding the replacement of her fractured,

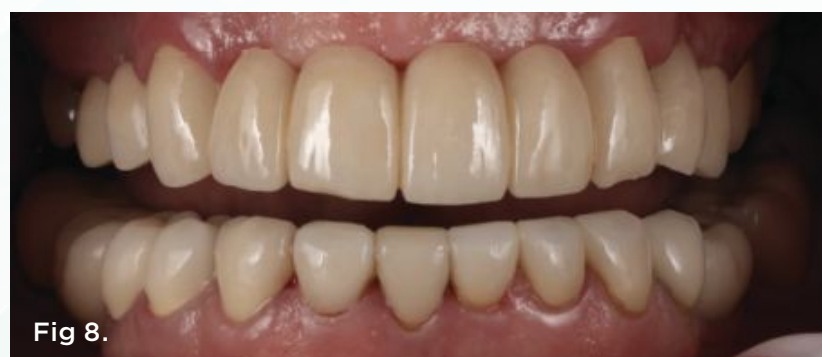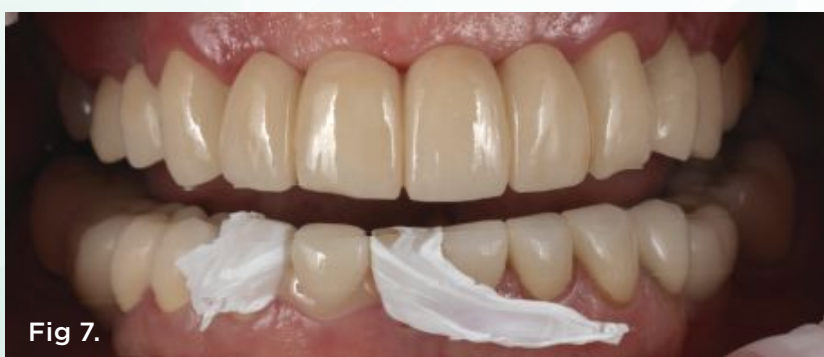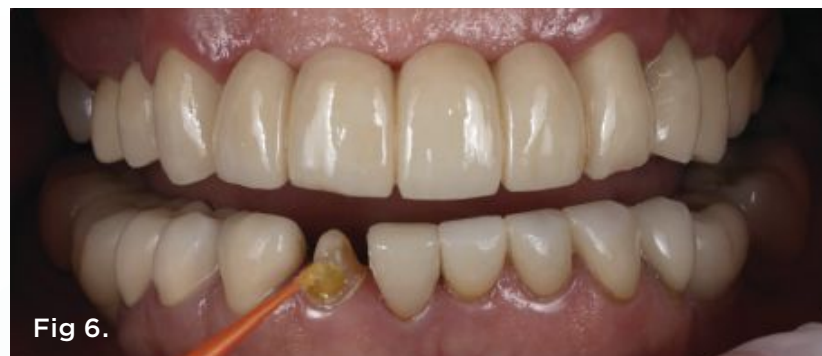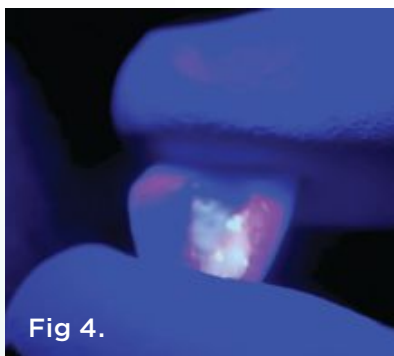


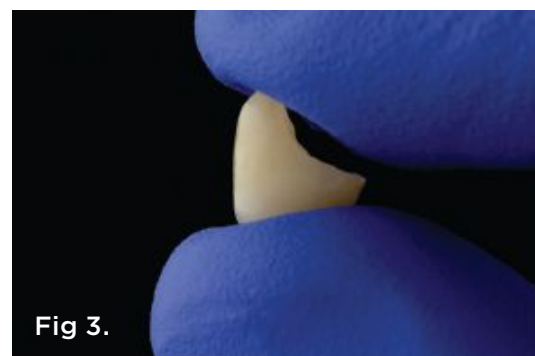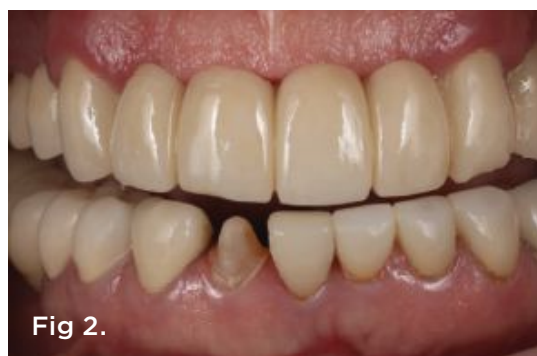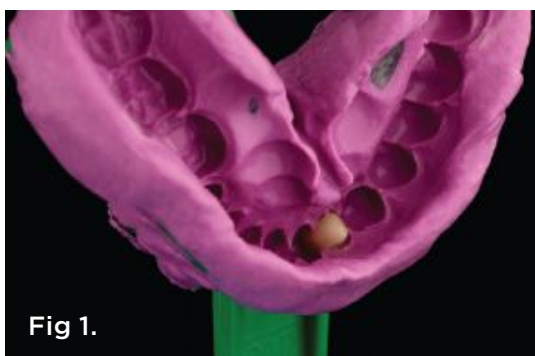Fig 1. Debonded lithium-disilicate crown (mandibular right lateral incisor), retained in diagnostic alginate impression. **Fig 2.** Frontal view of missing crown, mandibular right lateral incisor. **Fig 3.** Close-up view of debonded lithium-disilicate crown. **Fig 4.** An ultraviolet (UVA) LED light aided in detecting the fluorescent resin cement, which had adhered to the intaglio surface of the debonded crown. **Fig 5.** As was done in this case, with non-retentive tooth preparations, a light-cured universal adhesive may be brushed directly onto the tooth substrate in conjunction with a SARC. **Fig 6.** The adhesive sequence for re-cementation of the debonded lithium-silicate crown began with the application of a universal adhesive. **Fig 7.** After isolating the adjacent teeth and air-thinning and light-curing the adhesive, resin cement was placed inside the debonded restoration, which was seated and tack-cured. **Fig 8.** Final restorative result after removal of cured excess resin cement.

long-term provisional pontic restoration that was currently replacing her congenitally missing maxillary left lateral incisor (Figure 9). The patient was not amenable to a FDP utilizing her natural teeth as the abutments and had apprehension regarding the stability and durability of a resin-bonded FDP. Ultimately, she opted to have a single endosseous implant placed in the edentulous site.

In the maxillary anterior region, insufficient horizontal and/or vertical bone can sometimes preclude the ideal placement of an implant for an esthetic outcome.¹⁶ In the present case, the current depth and position of the implant that was placed necessitated the use of an implant abutment positioning jig to firmly hold the custom abutment in place while the abutment screw was tightened (Figure 10).¹⁷ Often, the final position of the implant and abutment complex demands the use of a cement-retained restoration to avoid the unesthetic emergence of an abutment screw-access channel through the facial aspect of the crown.¹⁸ A disadvantage of cement-retained implant restorations,

however, is the potential for the extrusion of excess residual cement into the sulcus during delivery, which may be difficult to identify.¹⁹ Insufficient removal of this excess cement can lead to peri-implantitis and possibly implant failure.²⁰

One of several techniques described in the literature to reduce the amount of excess resin cement around implant-retained restorations was used in this case, as shown in Figure 11 through Figure 13.²¹ After the application of an AEP to the opaquet, custom metal abutment, the definitive restoration was seated with minimal excess resin cement to clean-up and remove at the delivery appointment, and the patient was extremely satisfied with the final result (Figure 14).

Case 3: Zirconia-Based Restorations on Short Tooth Preparations

A 29-year-old female patient presented for a cosmetic evaluation of existing metal-ceramic restorations (MCRs) on her maxillary right lateral and both central incisors (Figure 15). Her dental history revealed incidence of blunt force trauma

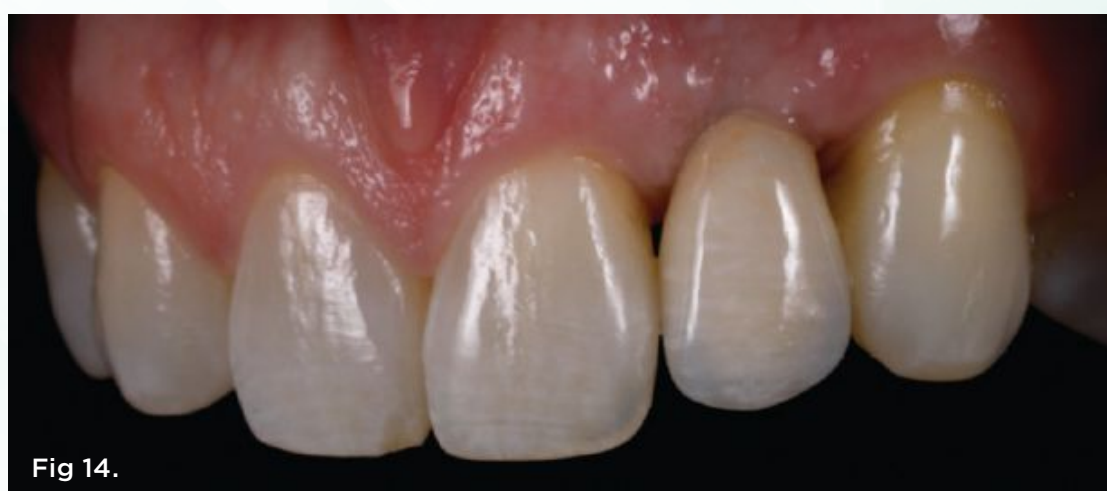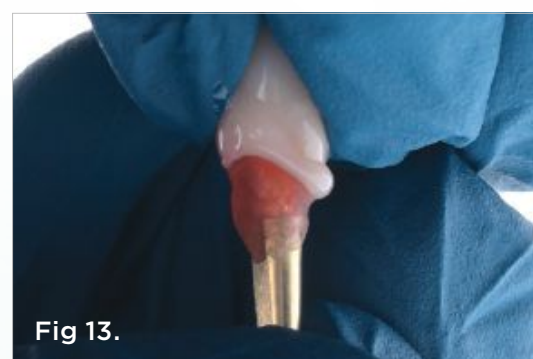
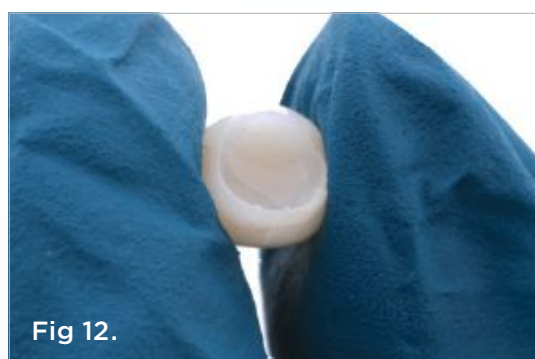
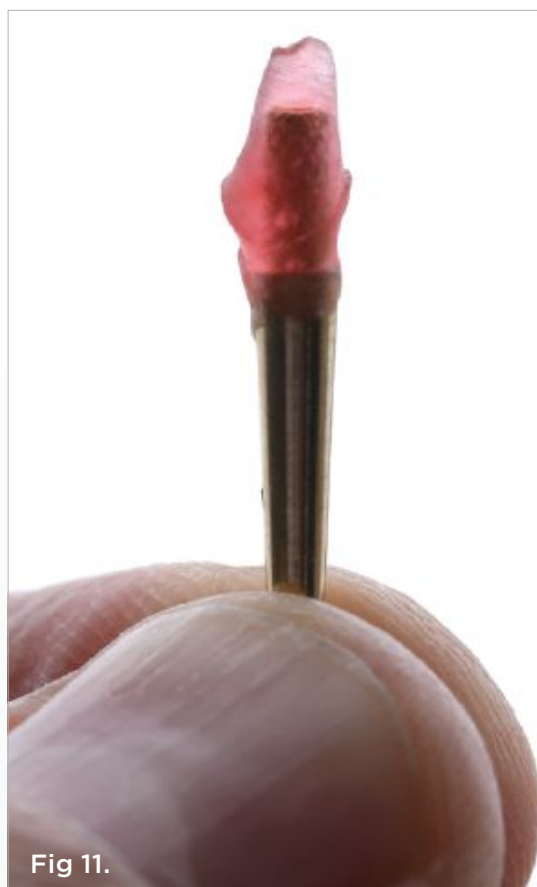

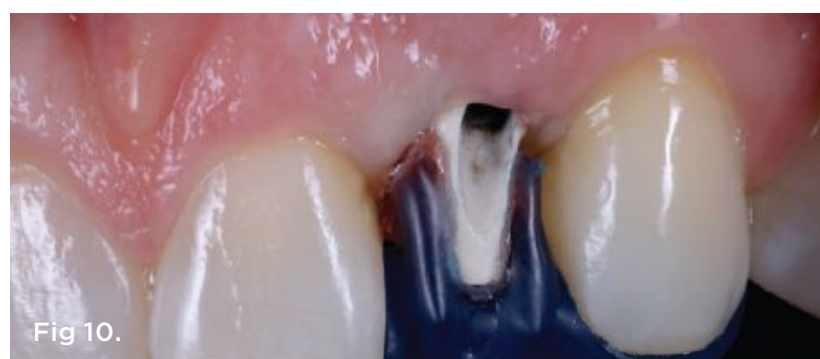
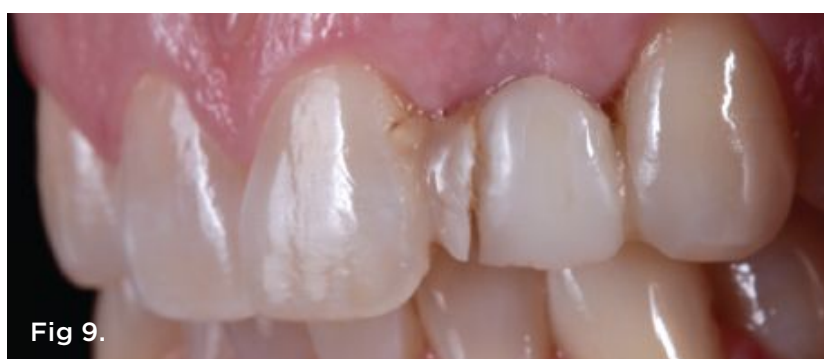Fig 9. Initial situation showing failed resin-bonded pontic, maxillary left lateral incisor. **Fig 10.** Non-retentive metal implant abutment with orientation jig in place. **Fig 11.** Laboratory-fabricated copy abutment. **Fig 12.** The implant crown was filled with SARC. **Fig 13.** Seating of the all-ceramic crown on the copy abutment to displace excess cement just prior to final delivery. **Fig 14.** Delivery of cement-retained implant crown demonstrating minimal tissue irritation following immediate clean-up of excess cement.

to the maxillary anterior teeth at age 11, followed by root canal therapy on teeth Nos. 7 through 10 and placement of her current full-coverage crowns (Nos. 7 through 9) at age 18.

The treatment plan would include whitening the patient's natural teeth, providing surgical crown lengthening to create harmony of the gingiva from teeth Nos. 6 through 11, and replacing the existing MCRs and tooth No. 10, which had recurrent decay, with layered zirconia-based crowns to achieve optimal esthetics.

Upon sectioning and removal of the MCRs and preparation of tooth No. 10 for a full-coverage crown (Figure 16), it was noted that the patient had relatively short clinical crowns. Because the retention and resistance to displacement of a restoration is largely dictated by the overall crown preparation (height, diameter, and taper),²² it was decided to follow the literature's recommendations to condition the intaglio surface of each restoration with airborne particle abrasion and apply an adhesive ceramic primer containing 10-MDP (G-Multi PRIMER™, GC America) to enhance the bond strength of the zirconia to the SARC (Figure 17).^{23,24} Each tooth preparation was additionally coated with an AEP and air-thinned for 10 seconds at maximum pressure. The contact of the AEP with the resin cement initiates a "touch-cure" reaction that begins the rapid polymerization of the SARC. The author has found this chemical catalyst to be particularly useful when dealing with zirconia-based restorations, as a clinically sufficient

amount of light may not be able to fully penetrate through the opaque zirconia ceramic to reach the dentin–cement interface.

Utilizing the layered zirconia restorations and translucent SARC, the final result achieved on the day of delivery was a highly esthetic outcome (Figure 18).

Conclusion

Adhesive chemistry resin cements afford dental providers the opportunity to efficiently treat numerous clinical scenarios that present every day. While not an exhaustive reference guide, the three case studies presented in this article represent common challenges involving indirect restorations that were successfully overcome with the use of a contemporary universal self-adhesive resin cement in conjunction with a universal light-cured adhesive or adhesive-enhancing primer.

DISCLOSURE

This article was commercially supported by GC America.

ABOUT THE AUTHOR

Miles R. Cone, DMD, MS, CDT

Private Practice, Portland, Maine; Diplomate, American Board of Prosthodontics; Fellow, American College of Prosthodontists

> To view the reference list, visit compendiumlive.com/go/cced2051.

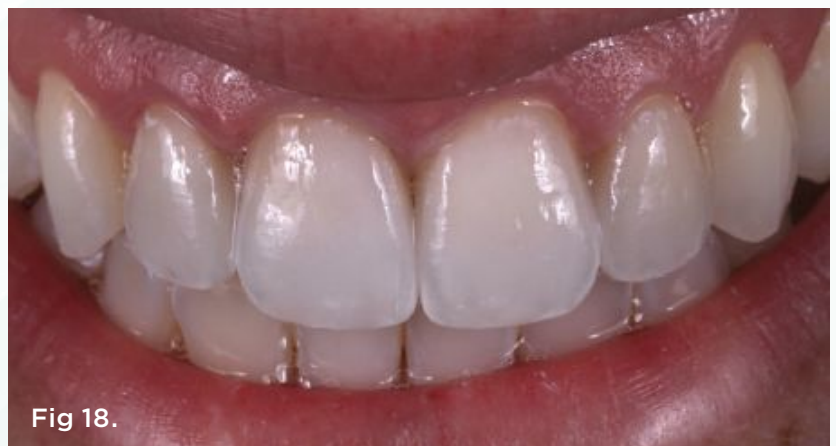
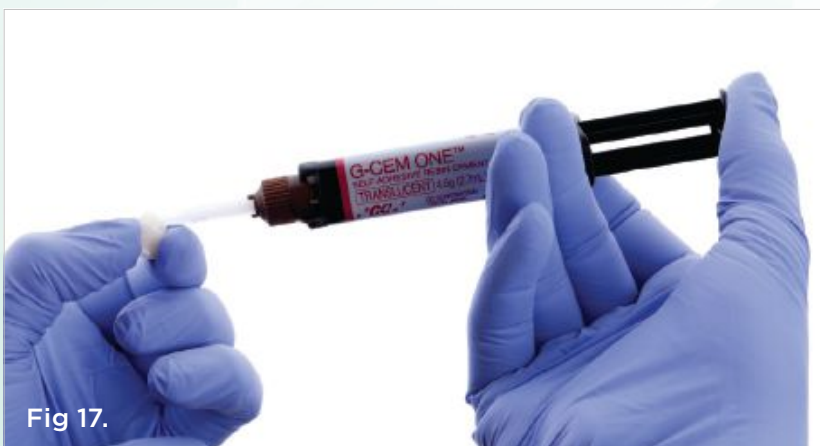
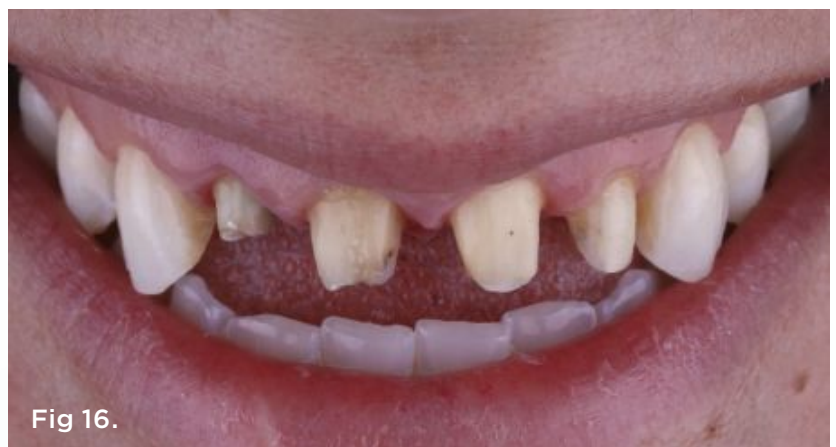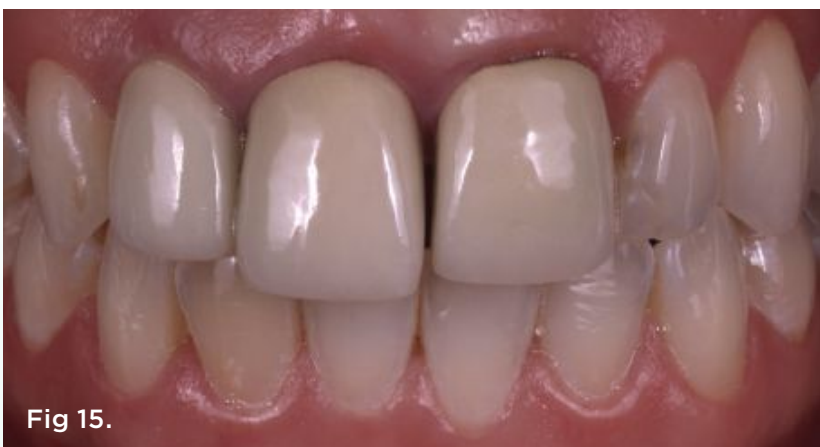Fig 15. Initial situation demonstrating cosmetic concerns with existing metal-ceramic crowns on the right lateral incisor, right central incisor, and left lateral incisor, and recurrent decay on the left lateral incisor of the maxilla. **Fig 16.** Sectioned and removed restorations/decay revealing clinically short tooth preparations. **Fig 17.** Following application of an adhesive primer to improve adhesion to the tooth substrate, a translucent SARC was used to lute the definitive full-coverage layered zirconia crowns. **Fig 18.** Final result on the day of delivery of four full-coverage layered zirconia cemented crowns.